CASE RECORDS of the MASSACHUSETTS GENERAL HOSPITAL

Founded by Richard C. Cabot

Nancy Lee Harris, M.D., *Editor*
Jo-Anne O. Shepard, M.D., *Associate Editor*
Sally H. Ebeling, *Assistant Editor*
Eric S. Rosenberg, M.D., *Associate Editor*
Alice M. Cort, M.D., *Associate Editor*
Christine C. Peters, *Assistant Editor*

Case 14-2009: A 36-Year-Old Man with Chest Pain, Dysphagia, and Pleural and Mediastinal Calcifications

Henning A. Gaissert, M.D., Nitra Piyavisetpat, M.D., and Eugene J. Mark, M.D.

From the Departments of Thoracic Surgery (H.A.G.), Radiology (N.P.), and Pathology (E.J.M.), Massachusetts General Hospital; and the Departments of Surgery (H.A.G.), Radiology (N.P.), and Pathology (E.J.M.), Harvard Medical School.

This article (10.1056/NEJMcpc0900637) was updated on October 7, 2009, at NEJM.org.

N Engl J Med 2009;360:1886-95.
Copyright © 2009 Massachusetts Medical Society.

PRESENTATION OF CASE

A 36-year-old man was admitted to the hospital because of chest pain, dysphagia, dyspnea, and pleural and mediastinal calcifications.

He had been well until approximately 6 years before admission, when a 182-kg weight fell on his shoulders while he was lifting weights at a gym. Intermittent left-sided chest pain occurred thereafter, gradually increased in severity, and responded transiently to nonsteroidal antiinflammatory medications and ice packs. Two and a half years before admission, dysphagia developed in association with solid foods and gradually increased in severity to include liquids; he lost 4.5 kg in weight. An esophagogram reportedly showed minimal tertiary contraction in the distal esophagus, with possible associated reflux and esophageal spasm, and no mucosal abnormality. Twenty-two months before admission, a chest radiograph at another hospital showed left pleural calcifications, which had not been present 3 years earlier.

A complete blood count and serum levels of glucose, electrolytes, calcium, phosphorus, magnesium, protein, and albumin were normal. The alkaline phosphatase level was 236 U per liter (reference range, 45 to 115). Results of pulmonary-function studies are shown in Table 1. A tuberculin skin test was nonreactive. A modified barium-swallow study showed high-grade stenosis of the distal esophagus at the gastroesophageal junction. Computed tomography (CT) of the chest revealed posterior mediastinal calcifications encircling the aorta and esophagus, extensive left pleural calcification, and right diaphragmatic plaques.

The patient was admitted to the other hospital. Esophagoscopy revealed a tight circumferential extrinsic compression at 40 cm, impassable to the endoscope, and no mucosal lesions. A left rib resection and pleural biopsy were performed. Pathological examination of the biopsy specimen revealed reactive fibrous tissue with ossification, no organisms, and no cancer. Cytologic examination of the pleural fluid revealed mesothelial cells and lymphocytes. A subculture of the specimen in anaerobic broth grew *Propionibacterium acnes;* other cultures were sterile.

Eighteen months before the current admission, the patient was admitted to this hospital for resection of the extrinsic esophageal stricture. On examination, breath sounds and chest-wall excursions were markedly diminished on the left side. A com-

Downloaded from www.nejm.org on October 17, 2009 . Copyright © 2009 Massachusetts Medical Society. All rights reserved.

plete blood count; serum levels of glucose, electrolytes, calcium, phosphorus, magnesium, protein, albumin, vitamin D, parathyroid hormone, iron, iron-binding capacity, vitamin B_{12}, folate, bilirubin, and alanine and aspartate aminotransferases; tests of coagulation and renal function; and serum protein electrophoresis were normal. Two units of blood drawn for future autotransfusion were positive on screening for antibody to the human T-cell lymphotropic virus type I (HTLV-I). The results of a Western blot test were indeterminate. Testing for antibody to human immunodeficiency virus (HIV) was negative.

At operation, an incision in the left sixth intercostal space disclosed pleural calcification, more than 1 cm thick, which prevented exposure of the left lung. A right thoracotomy revealed patches of wafer-thin calcification on the visceral pleura of the lower lobe, subpleural bone formation in the diaphragm, and a posterior mediastinal calcific mass surrounding the esophagus, inferior pulmonary ligament, vena cava, and aorta. A holmium laser was used to make an incision in the calcified tissue surrounding the esophagus, resulting in a release of the esophagus. After the release, a 60-French dilator was passed through the esophagus without resistance. A wedge biopsy of the right lower lobe was performed; pathological examination of the tissue revealed a dense fibroinflammatory process, with acute and chronic inflammation, focal necrosis, and ossification and no microorganisms. Cultures of the specimen grew propionibacterium species in the tube of thioglycollate broth and one colony of penicillium in fungal culture. Testing for antinuclear antibodies, anti–double-stranded DNA antibodies, and antibodies to anti–Scl-70 antibodies, and antibodies to *Aspergillus fumigatus*, *Thermoactinomyces sacchari*, *T. candidus*, *T. vulgaris*, *Saccharomonospora viridis*, *Saccharopolyspora rectivirgula* (formerly *Micropolyspora faeni*), and pigeon serum was negative.

Table 1. Results of Pulmonary-Function Tests.*

Value	22 Mo before Admission, Other Hospital	4 Mo before Admission, Other Hospital	1 Mo before Admission, This Hospital
Weight — kg	76	68	59
FEV_1 — liters (% of predicted value)	3.37 (82)	1.72 (43)	1.41 (35)
FVC — liters (% of predicted value)	4.44 (84)	1.75 (37)	1.41 (28)
FEV_1/FVC — ratio (% of predicted value)	0.76	0.98 (118)	1.00 (120)
FEF_{25-75} — liters/sec (% of predicted value)		3.17 (75)	3.38 (79)
Peak expiratory flow rate — liters/sec (% of predicted value)	9.93	5.43 (60)	3.85 (42)
Total lung capacity — liters (% of predicted value)	6.12 (85)	3.06 (48)	
Slow vital capacity — liters (% of predicted value)	4.35 (83)	1.8 (38)	
Functional residual capacity — liters (% of predicted value)	3.39 (86)	2.08 (65)	
Residual volume — liters (% of predicted value)	1.77 (92)	1.26 (76)	
Alveolar volume†		2.79 (38)	
Corrected carbon monoxide diffusion in the lung — ml/min/mm Hg (% of predicted value)	29.9 (95)	19.9 (63)	
Heart rate — beats/min			
At baseline		94	
After 7.5 min of exercise		133	
Oxygen saturation while breathing ambient air — %			
At baseline		98	
After 7.5 min of exercise		98	

* FEF_{25-75} denotes forced expiratory flow rate between 25 and 75% of the exhaled volume, FEV_1 forced expiratory volume in 1 second, and FVC forced vital capacity.
† Alveolar volume was measured at body temperature and ambient pressure and saturated with water vapor.

Downloaded from www.nejm.org on October 17, 2009 . Copyright © 2009 Massachusetts Medical Society. All rights reserved.

Dysphagia improved for 1 month and then recurred, with increasing dyspnea. Fiberoptic esophagoscopy at the other hospital identified a recurrent lower-esophageal stricture. Dilation was unsuccessful and resulted in a superficial mucosal injury. An electrocardiogram revealed sinus rhythm, nondiagnostic inferior Q waves, an incomplete right bundle-branch block, and nonspecific ST-segment and T-wave abnormalities. Bone densitometry was normal. One month later, the patient was readmitted to this hospital; right thoracotomy with resection of posterior mediastinal calcification, lateral suspension of the lower esophagus, and esophageal plication were performed. Pathological examination of the tissue showed fibrosis extending into the soft tissues of the chest wall, with multiple foci of active endochondral ossification adjacent to tufts of smooth muscle. Staining for keratin was negative. The pleural fluid revealed a total protein level of 4.1 g per deciliter and a triglyceride level of 30 mg per deciliter (0.3 mmol per liter). After discharge, a 4-week course of oral corticosteroids was administered. Eleven months before admission, dysphagia and dyspnea gradually recurred. During the next 9 months, esophagogastroduodenoscopy with dilatation was performed on four occasions. Dyspnea increased, and the patient was unable to continue working. There was no cough or sputum production. Results of pulmonary-function testing 4 months before admission are shown in Table 1. Echocardiography revealed no abnormalities.

Three months before admission, the patient began to have episodes of light-headedness lasting 4 to 5 minutes, without loss of consciousness and associated with weakness in the arms and legs, and he was admitted to another hospital. Orthostatic vital signs revealed mild postural changes. Electrocardiography showed sinus tachycardia. An echocardiogram at rest and magnetic resonance imaging (MRI) of the brain and cervical spine were reportedly normal. Telemetry, electroencephalography, and levels of cortisol, creatine kinase, and troponin were normal. He was transferred to this hospital. Electroencephalography was normal, and MRI of the heart and aorta with angiography showed the calcifications previously seen on CT and a free-flowing pericardial effusion, with no evidence of pericardial constriction or abnormal enhancement of the pericardium. Olanzapine was prescribed for anxiety.

One month later, the patient was readmitted to this hospital. He had a history of optical migraine headaches and a lipoma of the right chest wall. He was married with two children. He worked in construction and had worked in a motorcycle and bicycle repair shop as a teenager. He had traveled to the Caribbean in the past, smoked briefly as a teenager, and had stopped drinking alcohol several years earlier. His maternal grandmother had breast cancer in her early 50s; his parents and siblings were well. Oxycodone had caused tachycardia; there were no other known allergies. Medications included olanzapine, lorazepam, and ibuprofen. On examination, the pulse was 76 beats per minute, the blood pressure 150/70 mm Hg, the respiratory rate 16 breaths per minute, the oxygen saturation 99% while the patient was breathing oxygen (5 liters), and the temperature 35.8°C. The remainder of the examination was unchanged.

A diagnostic procedure was performed.

Table 2. Five Historically Successive Types of Exposure in Asbestos-Related Lung Disease and Malignant Mesothelioma.

Miners and millers, handling and refining the asbestos
Tradespeople, applying and removing the asbestos
Bystanders to asbestos in workplace, usually not aware of it
Family members, exposed at home to contaminated clothes
Occult exposure, no longer possible to identify because of lack of notation in the medical record, the passage of time and the failing of memory, the patient's or coworkers' lack of knowledge of the presence of asbestos in the workplace or of asbestos-containing products, or the death of the patient or coworkers

DIFFERENTIAL DIAGNOSIS

Dr. Henning A. Gaissert: I am this patient's thoracic surgeon and will discuss my differential diagnosis and management. This carpenter in his 30s presented with a symptom triad consisting of left-sided chest pain, dysphagia, and exertional dyspnea. A dense, calcific mass involving the left pleural space, chest wall, and mediastinum explained all symptoms. Despite examination of biopsy specimens of the left chest wall, the mediastinum, and the right pleura and lung, no diagnosis was made. Exposure to asbestos was uncertain.

My care of this patient had two goals: to make a diagnosis and to relieve his dysphagia. In the management of esophageal strictures that are due to luminal disease, dilatation, stenting, or other luminal intervention is commonly effective. None of these measures is appropriate when the obstruction is firm and extrinsic. Dilators and stents

Downloaded from www.nejm.org on October 17, 2009 . Copyright © 2009 Massachusetts Medical Society. All rights reserved.

do not increase the diameter of the lumen but may injure mucosa. In this case, resection of the bone around the esophagus by laser and bone cutter by means of thoracotomy, although unconventional, relieved dysphagia at first and allowed the patient to return to a regular diet.

May we review the imaging studies?

Dr. Nitra Piyavisetpat: A chest radiograph obtained 1 month before admission (Fig. 1A) shows calcification in the left pleural cavity with encasement of the left lung, which had progressed in comparison with earlier studies, with less volume than on the right side, and new calcifications in the right pleural cavity. After the administration of contrast material, an axial section of a chest CT scan at the level of the ventricles (Fig. 1B) shows dense calcification in the left pleural cavity, involving the visceral and parietal pleura, and in the right pleural cavity. The calcification extends into the posterior mediastinum and encases the aorta and esophagus, is inseparable from the posterior wall of the left ventricle, and extends along the left major fissure. There is extension of this calcification into the left chest wall posteriorly with soft-tissue masses within these areas of calcification. There is a small left pleural effusion, with no destruction of the ribs and no lymphadenopathy, and the lungs are clear.

A whole-body bone scan, obtained 1 month before admission and after the administration of technetium-99m–labeled methylene diphosphonate (Fig. 1C and 1D), shows the areas of abnormality that were seen on the chest CT, with intense activity within the left pleural cavity, areas of increased activity in the right pleural cavity, and no bone lesions.

Dr. Gaissert: Calcification or ossification involves most of the left pleural space and plaques on the right diaphragm, with no adjacent soft-tissue abnormality or significant pleural effusion. Is this calcium or bone? Calcification involves deposition of calcium salts into tissues due to inflammation, infection, or metabolic derangement. Heterotopic bone, in contrast, is generated by osteoblasts, either benign or malignant. Typical patterns of opacification often allow this distinction on radiographs, but these radiographs were shown to both orthopedic and thoracic radiologists, who had ideas but could make no diagnoses.

Many disorders of the chest are accompanied by calcification, but the calcifications themselves rarely cause symptoms or exist without other tissue elements, which they did in this case. The evaluation proceeds from two questions. First, is the localized process associated with a systemic abnormality? Second, what is the tissue of origin?

SYSTEMIC DISORDERS WITH PLEURAL CALCIFICATION

Hypercalcemia is associated with extraosseous calcification. Elevation of the serum calcium level may be seen in leukemias or lymphomas, including HTLV-I–associated adult T-cell lymphoma–leukemia; this patient had an initial suggestion of HTLV-I infection, but confirmatory testing was negative and his lymphocyte count was normal. Furthermore, the serum calcium, parathyroid hormone, and vitamin D levels were normal, as were the results of renal-function tests. In the absence of liver disease, medication use, and fractured bones, the presence of an elevated alkaline phosphatase level suggests bone disease, possibly a primary bone tumor or bone metastasis. We wondered whether the presence of *P. acnes* in anaerobic cultures obtained from pleural fluid on two separate occasions could be related to this process, but there was no evidence to tie this organism to pleural calcification. Thus, there is no systemic disorder to account for calcific pleural masses in this case.

DISEASES OF THE CHEST ASSOCIATED WITH CALCIFICATION

Parenchymal Lung Diseases

The observed process does not arise from within lung parenchyma. Thus, we may rule out tumors that contain calcific deposits, such as hamartoma, carcinoid tumor, primary bronchogenic carcinoma,[1] and most pulmonary metastases; furthermore, the amount of calcium in these types of lesions is minor in comparison to the amount of tumor. On the basis of the absence of parenchymal calcification, we may also exclude a number of diffuse disorders of the lung sometimes associated with respiratory failure: sarcoidosis, amyloidosis, silicosis, pulmonary fibrosis, rheumatic heart disease, and alveolar microlithiasis. These conditions have bilateral lung involvement, with sparing of the pleural space, features that are in contrast to the observations in this case.

Granulomatous disease due to tuberculosis or histoplasmosis may cause pulmonary or mediastinal calcifications. Tuberculosis is unlikely in view of the patient's negative purified-protein-derivative test. Histoplasmomas are focal parenchymal masses of calcium that may enlarge over a period

Downloaded from www.nejm.org on October 17, 2009 . Copyright © 2009 Massachusetts Medical Society. All rights reserved.

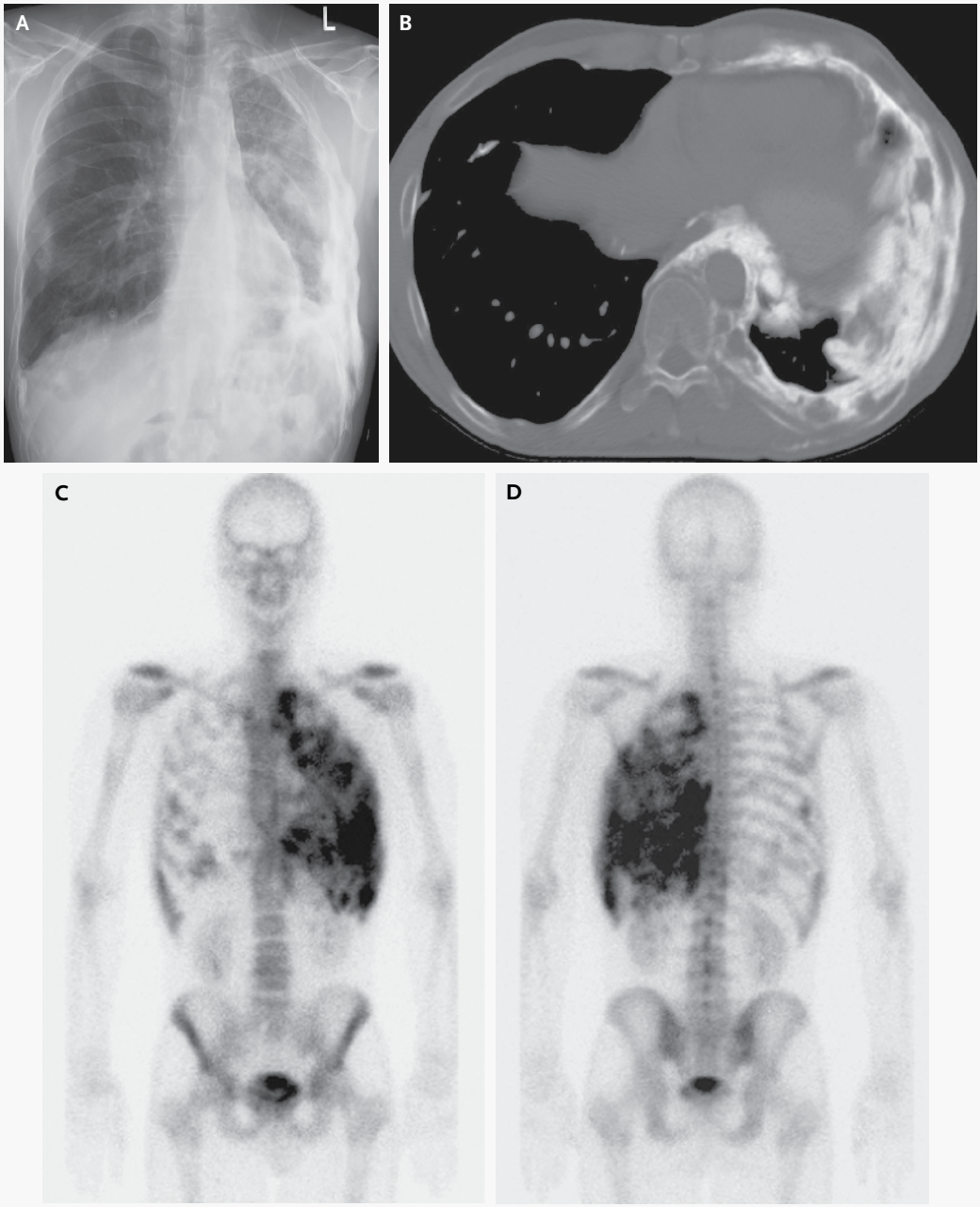

Figure 1. Imaging Studies.
A chest radiograph (Panel A) obtained 1 month before admission shows calcification in the left lower hemithorax and scattered right pleural calcifications. There is encasement of the left lung. A CT scan in bone windows at the level of the ventricles (Panel B) shows extensive calcification of the left pleural space, extending into the chest wall around the heart and posterior mediastinum, with encasement of the esophagus and aorta. Calcification is present in the right pleural space along the major fissure. A bone scan obtained after the administration of technetium-99m–labeled methylene diphosphonate (Panels C and D) shows intense activity in the left pleural space.

of years to acquire a central core or ring of calcium with a characteristic mulberry shape, unlike the lesions in this case.

Mediastinal Diseases

Parts of the mass extended into the mediastinum to encase large vessels and the lower esophagus.

Downloaded from www.nejm.org on October 17, 2009 . Copyright © 2009 Massachusetts Medical Society. All rights reserved.

Mediastinal masses may lead to dysphagia. The most common mediastinal cause of dysphagia extrinsic to the esophagus is granulomatous disease involving the subcarinal lymph nodes.[2] Although diffuse mediastinal fibrosis rarely contains calcification,[3] localized fibrosing mediastinitis due to histoplasmosis may contain calcification. Inflamed and sometimes calcified lymph nodes may form a matted mass adhering to esophageal muscle that can lead to ulceration or formation of a fistula between the esophagus and the airway. Early in this patient's course, fibrosing mediastinitis due to histoplasmosis was a serious consideration. Endoscopy, however, revealed no esophageal mucosal lesions, and a complement-fixation test for histoplasma was negative.

DISEASES OF THE CHEST WALL

We ought to consider masses in the chest wall, since the calcifications were contiguous to the bony chest and formed spicules in muscle outside the ribs. A previous case study[4] has dealt in detail with tumors of the chest wall, and I will therefore focus on the chest-wall masses that are relevant to our discussion.

Non-Neoplastic Conditions

Errors of bone development, notably fibrous dysplasia and melorheostosis,[5] lead to malformed individual bones, but not to extensive chest-wall masses. Myositis ossificans is a benign condition; the nonhereditary type arises as a local calcified mass in response to injury[4]; this patient reported an injury to the chest several years before the onset of dysphagia, but myositis ossificans could not explain the extensive calcification that eventually developed. The hereditary disorder fibrodysplasia ossificans progressiva, caused by a mutation of the bone morphogenetic protein receptor type 1,[6] leads to extensive soft-tissue calcifications throughout the body. Although fibrodysplasia may be associated with limitations of chest-wall expansion,[7] the rapid evolution of restrictive lung physiology in our patient, with a drop in the forced vital capacity from 84 to 28% of the predicted value over a period of 20 months, surely outpaces any hereditary disorder at that age. In fibrodysplasia, furthermore, deposition of calcium in the soft tissues typically spares the heart and diaphragm.

Osteosarcoma

Primary osteosarcoma may arise from the ribs, scapula, or clavicle and forms a soft-tissue mass with characteristic sunburst ossification. Metastatic or primary pleural osteosarcoma may consist entirely of bone, without a soft-tissue component, and may form plaques and diffuse bone[8] similar to those in this case. Primary osteosarcoma in extraskeletal locations is extremely rare, with only a few reported cases of pleural origin.[9,10] The radionuclide bone scan showed uptake of radiolabel in the calcific mass and no separate primary lesion. If we assume the patient's disease is osteosarcoma, we are observing either the primary lesion or metastatic pleural tumor of unknown origin. Nothing short of biopsy will resolve this question.

Mesothelioma

The only other malignant pleural tumor with the capacity of osseous differentiation is mesothelioma.[11] Mesothelioma may involve the mediastinum and produce esophageal obstruction[12] and may be associated with calcification and bone formation. Hyaline plaques may have calcified by the time a mesothelioma arises,[13] and osseous differentiation may occur focally in sarcomatous and biphasic mesothelioma,[14,15] typically seen on CT as the focal presence of bone within soft-tissue masses and adjacent to pleural effusions.[16,17] The unusual feature of this case is the total absence of a soft-tissue component, although such a case has been reported.[18]

Although all his caregivers considered mesothelioma at the time of first presentation, this patient was young, and definite exposure to asbestos was not established. Neither circumstance, however, excludes mesothelioma: indolent well-differentiated papillary mesothelioma[19] and aggressive deciduoid mesothelioma of the pleura and peritoneum[20] occur in young patients without known asbestos exposure. Nonetheless, a diagnosis of mesothelioma could not be accepted without histologic confirmation. One particular feature of mesothelioma with osseous differentiation makes it challenging to obtain an adequate sample for diagnosis: malignant cells may be found only in the narrow border zone of bone formation around the trabeculae.[21] Biopsy specimens lacking enough border zone may not provide sufficient malignant cells for diagnosis.

SUMMARY

This patient's illness remained undiagnosed during a detailed, prolonged investigation under my care. How can a physician guide a patient when

Downloaded from www.nejm.org on October 17, 2009 . Copyright © 2009 Massachusetts Medical Society. All rights reserved.

the diagnosis is unknown? For the patient, uncertainty about the diagnosis is in many ways worse than certainty about a condition with a poor prognosis. Three previous biopsies had failed to yield a diagnosis. After each procedure, the patient needed to recover and understand the usefulness of another procedure; meanwhile, his general condition deteriorated. At the time of the current admission, recurrent dysphagia provided additional evidence that the underlying cause was probably malignant. We did not expect to find a reversible cause of his problem, and the mass was clearly unresectable. Yet, the patient, his family, and caregivers all wanted a diagnosis even though an incurable disease was suspected. In an attempt to obtain diagnostic tissue, I performed a left anterior minithoracotomy (Chamberlain procedure); I could not make an incision in the calcific mass with scissors, and I used a rongeur to obtain fragments of calcified mediastinal and pleural tissue for pathological examination.

DR. HENNING A. GAISSERT'S DIAGNOSIS

Malignant mesothelioma with ossification.

PATHOLOGICAL DISCUSSION

Dr. Eugene J. Mark: The biopsy specimen showed in large part abnormal bone (Fig. 2) and to a small degree abnormal cartilage and proliferation of spindle cells within the interstices of the bone. The spindle-cell proliferation extended into fibroadipose tissue. On the basis of the infiltrative nature of the process pathologically and the course of the disease, we made a diagnosis of diffuse malignant mesothelioma of mesenchymal type, fibrosarcomatous subtype, with marked osteocartilaginous differentiation. On immunohistochemical studies, the cells stained only for vimentin and CD34, which are nonspecific, and did not stain for keratins, S-100 protein, calretinin, smooth-muscle actin, or thyroid transcription factor 1. Diffuse malignant mesothelioma of this type often has no specific immunopathologic staining pattern.[22]

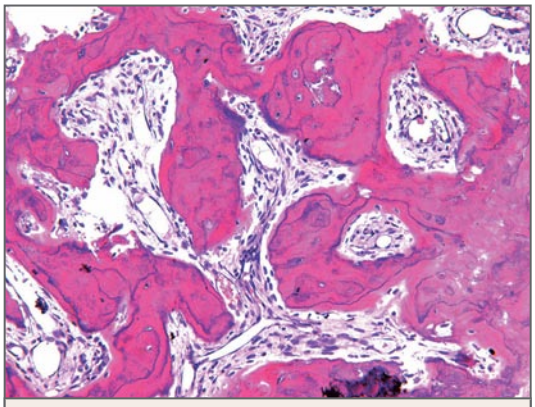

Figure 2. Mediastinoscopic Biopsy Specimen of Malignant Spindle-Cell Tumor with Marked Osseous Differentiation (Hematoxylin and Eosin).

Osteocartilaginous differentiation in diffuse malignant mesothelioma occurs in a small percentage of cases[15,16] but rarely to the extent seen in this case. The most pressing problem in the diagnosis of diffuse malignant mesothelioma is usually in distinguishing it from a reactive mesothelial proliferation.[23] Focal osseous differentiation, the more common situation, usually does not create problems in obtaining the tissue at surgery or in making a diagnosis of a malignant tumor. It is uncertain why the extensive ossification occurred here.

Dr. Gaissert: After the diagnosis of mesothelioma was made, we again questioned the patient and his family about asbestos exposure. When the patient was 2 years of age, his father left the home; his occupation was unknown. While he was in high school, the patient had worked repairing bicycles and motorcycles and cleaning the repair shop, and when he was in his early 20s, he became a carpenter, but he was not known to have been exposed to asbestos at work. We recently learned that while he was in high school, extensive removal of asbestos occurred in the school.

The patient was seen by the thoracic oncology service and was treated with a regimen of gemcitabine and pemetrexed. He had some relief of dysphagia and dyspnea but continued to have frequent episodes of light-headedness, weakness, and anxiety. Four months after discharge, he was readmitted to another hospital with increasing symptoms of anxiety, and shortly after admission, was found in cardiac arrest with pulseless electric activity; resuscitation was unsuccessful. Permission was granted for an autopsy restricted to the chest.

Dr. Mark: At autopsy, hard, bony tumor encased the mediastinal structures, including the esophagus, vena cava, aorta (Fig. 3A), and the hilum of the left lung, including the main pulmonary ar-

Downloaded from www.nejm.org on October 17, 2009 . Copyright © 2009 Massachusetts Medical Society. All rights reserved.

tery. The lumen of the esophagus was narrowed to 1 cm in diameter. The left pleural cavity was virtually obliterated by the tumor, which arose from the pleura, was not separable from the thoracic wall, measured up to 9 cm in thickness, encased the lung, invaded the left hemidiaphragm, and extensively infiltrated the pericardium, involving more than 50% of the surface. Calcified plaques were present on the right visceral pleura. Histopathologically, infiltrative bony tumor with relatively inconspicuous spindle-cell proliferation grew linearly along and in the pleura with relative sparing of subjacent lung (Fig. 3B), extending focally into lobular septa and alveolar walls (Fig. 3C). The tumor also infiltrated the walls of the esophagus and major bronchi, as well as the pericardium. In a few regions, more obvious cytologic features of malignancy were present, including pleomorphic nuclei and the formation of storiform patterns (Fig. 3D). The right pleural plaques also represented malignant mesothelioma. Evidence of asbestosis was not found in the lungs.

Diffuse malignant mesothelioma is a sign that this patient was exposed to and inhaled asbestos.[24-30] As in this case, a history of exposure to asbestos often is not found initially but later becomes apparent after additional occupational history is taken by trained personnel.[31,32] Diffuse malignant mesothelioma was described by Selikoff as having occurred in three waves, with different types of exposures occurring over time; we now recognize five waves (Table 2).[24] Occupational exposure through work in shipyards and construction is the most commonly recognized cause of the disease, but spousal or household exposure[33,34] is also well established as a cause; other exposures not commonly appreciated are work with drywall, brakes, gaskets, packing, and asbestos-cement pipe.[24] Low levels of exposure to asbestos, includ-

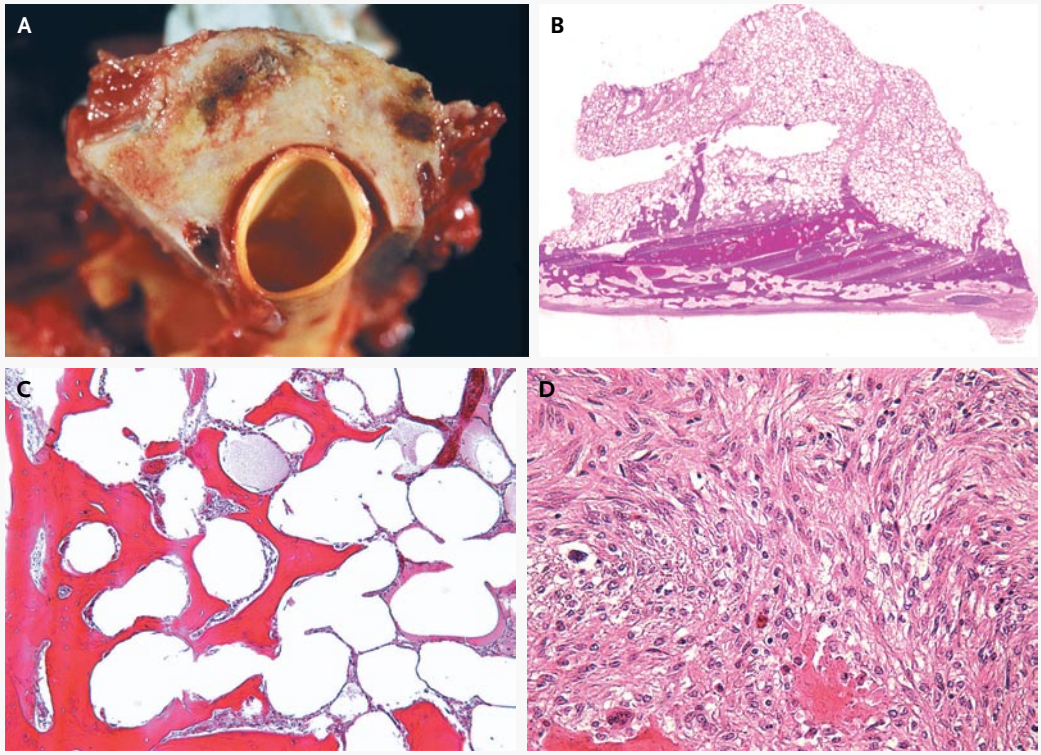

Figure 3. Pathological Findings at Autopsy.

A gross photograph (Panel A) shows solid, bony tumor encasing the aorta. On low-power microscopical examination (Panel B, hematoxylin and eosin), diffuse malignant mesothelioma consisting principally of bone spreads linearly along the visceral pleura. At higher magnification (Panel C, hematoxylin and eosin), bone invades the subpleural lung along the alveolar walls; there is almost no cellular tumor in this section. In another area (Panel D, hematoxylin and eosin), a malignant hypercellular spindle-cell tumor with a storiform pattern is seen.

Downloaded from www.nejm.org on October 17, 2009 . Copyright © 2009 Massachusetts Medical Society. All rights reserved.

ing cumulative exposures to amounts that probably were far below limits adopted in most industrial countries during the 1980s, have been described by many authors as causing diffuse malignant mesothelioma; such a low-level exposure may have occurred in this case.[23,35,36] The latency period for development of mesothelioma is generally considered to be at least 20 years. In this case, it is likely that exposure occurred during adolescence, either while the patient was working on brakes or at the high school where asbestos-removal was occurring or both; additional exposures may have occurred during his work in construction.

The cause of death in this case was an acute extensive myocardial infarction involving the posterior papillary muscle. There was focal interstitial fibrosis and myocyte hypertrophy, suggesting a component of chronic ischemia. There was no coronary-artery stenosis, and we speculated that pericardial constriction caused by the tumor may have caused myocardial ischemia. There was hemopericardium, which we attributed to the attempts at resuscitation.

Dr. Nancy Lee Harris (Pathology): This patient died of myocardial infarction shortly after what was considered to be an anxiety or panic attack. In retrospect, I wonder whether these attacks were related to pericardial constriction by the tumor and may have had a physiological rather than an emotional cause.

I have invited the patient's widow to comment on the patient's and the family's experience.

The Patient's Wife: My husband had an undiagnosed illness for almost 5 years. Having an undiagnosed illness made us feel hopeless about our situation. It is difficult to accept and emotionally work through an illness if you don't even know what you have. Unfortunately, the lack of a diagnosis also affected our support system of family and friends, since some of them began to think we might be exaggerating my husband's health problems. Last and most important was the time and energy we spent researching on our own and the constant appointments with one doctor after another. Our last years together were wasted searching for an answer instead of being spent enjoying and making memories with our two young boys, who were only 3 and 5 years old when my husband died.

ANATOMICAL DIAGNOSES

Diffuse malignant mesothelioma, with extensive osseous differentiation, involving the pleura, chest wall, lung, mediastinum, esophagus, and pericardium.

Acute myocardial infarction.

Dr. Mark reports serving as an expert witness at trial for people who had diffuse malignant mesothelioma and who believed that they had been harmed by asbestos.

We thank Dr. Amita Sharma for advice and assistance.

REFERENCES

1. Usami N, Yoshioka H, Mori S, Imaizumi M, Nagasaka T, Ueda Y. Primary lung adenocarcinoma with heterotopic bone formation. Jpn J Thorac Cardiovasc Surg 2005;53:102-5.
2. Savides TJ, Gress FG, Wheat LJ, Ikenberry S, Hawes RH. Dysphagia due to mediastinal granulomas: diagnosis with endoscopic ultrasonography. Gastroenterology 1995;109:366-73.
3. Sherrick AD, Brown LR, Harms GF, Myers JL. The radiographic findings of fibrosing mediastinitis. Chest 1994;106:484-9.
4. Case Records of the Massachusetts General Hospital (Case 38-1994). N Engl J Med 1994;331:1079-84.
5. Freyschmidt J. Melorheostosis: a review of 23 cases. Eur Radiol 2001;11:474-9.
6. Shore EM, Xu M, Feldman GJ, et al. A recurrent mutation in the BMP type I receptor ACVR1 causes inherited and sporadic fibrodysplasia ossificans progressiva. Nat Genet 2006;38:525-7.
7. Kussmaul WG, Esmail AN, Sagar Y, Ross J, Gregory S, Kaplan FS. Pulmonary and cardiac function in advanced fibrodysplasia ossificans progressiva. Clin Orthop Relat Res 1998;346:104-9.
8. Rastogi R, Garg R, Thulkar S, Bakhshi S, Gupta A. Unusual thoracic CT manifestations of osteosarcoma: review of 16 cases. Pediatr Radiol 2008;38:551-8.
9. Chandak P, Hunt I, Rawlins R, Lucas S, Treasure T. Bone or pleura? Primary pleural osteosarcoma. J Thorac Cardiovasc Surg 2007;133:587-8.
10. Stark P, Smith DC, Watkins GE, Chun KE. Primary intrathoracic extraosseous osteogenic sarcoma: report of three cases. Radiology 1990;174:725-6.
11. Case Records of the Massachusetts General Hospital (Case 20-1997). N Engl J Med 1997;336:1895-903.
12. Togashi K, Hosaka Y, Sato K. Sarcomatoid pleural mesothelioma presenting as posterior mediastinal tumor with dysphagia. Kyobu Geka 2007;60:49-52. (In Japanese.)
13. Clarke CC, Mowat FS, Kelsh MA, Roberts MA. Pleural plaques: a review of diagnostic issues and possible nonasbestos factors. Arch Environ Occup Health 2006;61:183-92.
14. Goldstein B. Two malignant pleural mesotheliomas with unusual histological features. Thorax 1979;34:375-9.
15. Yousem SA, Hochholzer L. Malignant mesotheliomas with osseous and cartilaginous differentiation. Arch Pathol Lab Med 1987;111:62-6.
16. Raizon A, Schwartz A, Hix W, Rockoff SD. Calcification as a sign of sarcomatous degeneration of malignant pleural mesotheliomas: a new CT finding. J Comput Assist Tomogr 1996;20:42-4.
17. Persaud V, Bateson EM, Bankay CD. Pleural mesothelioma associated with massive hepatic calcification and unusual metastases. Cancer 1970;26:920-8.
18. Suen HC, Sudholt B, Anderson WM, Lakho MH, Daily BB. Malignant mesothelioma with osseous differentiation. Ann Thorac Surg 2002;73:665.

Downloaded from www.nejm.org on October 17, 2009 . Copyright © 2009 Massachusetts Medical Society. All rights reserved.

19. Butnor KJ, Sporn TA, Hammar SP, Roggli VL. Well-differentiated papillary mesothelioma. Am J Surg Pathol 2001;25:1304-9.
20. Ordóñez NG. Epithelial mesothelioma with deciduoid features: report of four cases. Am J Surg Pathol 2000;24:816-23.
21. Kiyozuka Y, Miyazaki H, Yoshizawa K, et al. An autopsy case of malignant mesothelioma with osseous and cartilaginous differentiation: bone morphogenetic protein-2 in mesothelial cells and its tumor. Dig Dis Sci 1999;44:1626-31.
22. Ordóñez NG. What are the current best immunohistochemical markers for the diagnosis of epithelioid mesothelioma? A review and update. Hum Pathol 2007;38:1-16.
23. Kradin RL, Mark EJ. Distinguishing benign mesothelial hyperplasia from neoplasia: a practical approach. Semin Diagn Pathol 2006;23:4-14.
24. Mark EJ, Kradin RL. Pathological recognition of diffuse malignant mesothelioma of the pleura: the significance of the historical perspective as regards this signal tumor. Semin Diagn Pathol 2006;23:25-34.
25. Landrigan PJ, Garg A. Chronic effects of toxic environmental exposures on children's health. J Toxicol Clin Toxicol 2002;40:449-56.
26. Hodgson JT, McElvenny DM, Darnton AJ, Price MJ, Peto J. The expected burden of mesothelioma mortality in Great Britain from 2002 to 2050. Br J Cancer 2005;92:587-93.
27. Leigh J, Davidson P, Hendrie L, Berry D. Malignant mesothelioma in Australia, 1945-2000. Am J Ind Med 2002;41:188-201.
28. Peto J, Hodgson JT, Matthews FE, Jones JR. Continuing increase in mesothelioma mortality in Britain. Lancet 1995;345:535-9.
29. Robinson BW, Lake RA. Advances in malignant mesothelioma. N Engl J Med 2005;353:1591-603.
30. Tossavainen A. Global use of asbestos and the incidence of mesothelioma. Int J Occup Environ Health 2004;10:22-5.
31. Nam JM, Rice C, Gail MH. Comparison of asbestos exposure assessments by next-of-kin respondents, by an occupational hygienist, and by a job-exposure matrix from the National Occupational Hazard Survey. Am J Ind Med 2005;47:443-50.
32. Wolf KM, Piotrowski ZH, Engel JD, Bekeris LG, Palacios E, Fisher KA. Malignant mesothelioma with occupational and environmental asbestos exposure in an Illinois community hospital. Arch Intern Med 1987;147:2145-9.
33. Miller A. Mesothelioma in household members of asbestos-exposed workers: 32 United States cases since 1990. Am J Ind Med 2005;47:458-62.
34. Schneider J, Straif K, Woitowitz HJ. Pleural mesothelioma and household asbestos exposure. Rev Environ Health 1996;11:65-70.
35. Iwatsubo Y, Pairon JC, Boutin C, et al. Pleural mesothelioma: dose-response relation at low levels of asbestos exposure in a French population-based case-control study. Am J Epidemiol 1998;148:133-42.
36. Welch LS, Acherman YI, Haile E, Sokas RK, Sugarbaker PH. Asbestos and peritoneal mesothelioma among college-educated men. Int J Occup Environ Health 2005;11:254-8.

Copyright © 2009 Massachusetts Medical Society.

LANTERN SLIDES UPDATED: COMPLETE POWERPOINT SLIDE SETS FROM THE CLINICOPATHOLOGICAL CONFERENCES

Any reader of the *Journal* who uses the Case Records of the Massachusetts General Hospital as a teaching exercise or reference material is now eligible to receive a complete set of PowerPoint slides, including digital images, with identifying legends, shown at the live Clinicopathological Conference (CPC) that is the basis of the Case Record. This slide set contains all of the images from the CPC, not only those published in the *Journal*. Radiographic, neurologic, and cardiac studies, gross specimens, and photomicrographs, as well as unpublished text slides, tables, and diagrams, are included. Every year 40 sets are produced, averaging 50-60 slides per set. Each set is supplied on a compact disc and is mailed to coincide with the publication of the Case Record.

The cost of an annual subscription is $600, or individual sets may be purchased for $50 each. Application forms for the current subscription year, which began in January, may be obtained from the Lantern Slides Service, Department of Pathology, Massachusetts General Hospital, Boston, MA 02114 (telephone 617-726-2974) or e-mail Pathphotoslides@partners.org.

Downloaded from www.nejm.org on October 17, 2009 . Copyright © 2009 Massachusetts Medical Society. All rights reserved.

CORRECTION

Case 14-2009: A 36-Year-Old Man with Chest Pain, Dysphagia, and Pleural and Mediastinal Calcifications

Case 14-2009: A 36-Year-Old Man with Chest Pain, Dysphagia, and Pleural and Mediastinal Calcifications . The disclosure statement (page 1894) should have read, ``Dr. Mark reports serving as an expert witness at trial for people who had diffuse malignant mesothelioma and who believed that they had been harmed by asbestos.´´ The article has been corrected at NEJM.org.

N Engl J Med 2009;361:1516-b

Downloaded from www.nejm.org on October 17, 2009 . Copyright © 2009 Massachusetts Medical Society. All rights reserved.